



POLICY STATEMENT

Red Reflex Examination in Neonates, Infants, and Children

Organizational Principles to Guide and Define the Child Health Care System and/or Improve the Health of All Children

AMERICAN ACADEMY OF PEDIATRICS

Section on Ophthalmology

AMERICAN ASSOCIATION FOR PEDIATRIC OPHTHALMOLOGY AND STRABISMUS

AMERICAN ACADEMY OF OPHTHALMOLOGY

AMERICAN ASSOCIATION OF CERTIFIED ORTHOPTISTS

ABSTRACT

Red reflex testing is an essential component of the neonatal, infant, and child physical examination. This statement, which is a revision of the previous policy statement published in 2002, describes the rationale for testing, the technique used to perform this examination, and the indications for referral to an ophthalmologist experienced in the examination of children. *Pediatrics* 2008;122:1401–1404

INTRODUCTION

Red reflex testing is vital for early detection of vision- and potentially life-threatening abnormalities such as cataracts, glaucoma, retinoblastoma, retinal abnormalities, systemic diseases with ocular manifestations, and high refractive errors. The American Academy of Pediatrics currently recommends red reflex assessment as a component of the eye evaluation in the neonatal period and during all subsequent routine health supervision visits¹ (see also Bright Futures, available at www.brightfutures.org).

The red reflex test uses transmission of light from an ophthalmoscope through all the normally transparent parts of a subject's eye, including the tear film, cornea, aqueous humor, crystalline lens, and vitreous humor. This light reflects off the ocular fundus, is transmitted back through the optical media and through the aperture of the ophthalmoscope, and is imaged in the eye of the examiner. Any factor that impedes or blocks this optical pathway will result in an abnormality of the red reflex. An abnormal red reflex can result from mucus or other foreign bodies in the tear film, corneal opacities, aqueous opacities, iris abnormalities affecting the pupillary aperture (pupil), cataracts, vitreous opacities, and retinal abnormalities including tumors or chorioretinal colobomata. Unequal or high refractive errors (need for glasses) and strabismus (eye misalignment) may also produce abnormalities or asymmetry of the red reflex. There may be significant variation in the red reflex in children from different racial or ethnic groups resulting from their differing levels of pigmentation of the ocular fundus. Nevertheless, the pediatrician who performs these evaluations on a regular basis will quickly become familiar with these variations in normalcy.

PERFORMING THE RED REFLEX TEST

The red reflex test is properly performed by holding a direct ophthalmoscope close to the examiner's eye with the ophthalmoscope lens power set at "0" (see Fig 1). In a darkened room, the ophthalmoscope light should then be projected onto both eyes of the child simultaneously from approximately 18 inches away. To be considered normal, a red reflex should emanate from both eyes and be symmetric in character. Dark spots in the red reflex, a markedly diminished reflex, the presence of a white reflex, or asymmetry of the reflexes (Bruckner reflex) are all indications for referral to an ophthalmologist who is experienced in the examination of children. The exception to this rule is a transient opacity from mucus in the tear film that is mobile and completely disappears with blinking.

All infants and children with a positive family history of retinoblastoma; congenital, infantile, or juvenile cataracts; glaucoma; or retinal abnormalities should be referred to an ophthalmologist who is experienced in the examination of children for a complete eye examination regardless of the status of the red reflex, because these children are at high risk of vision- and potentially life-threatening eye abnormalities. Age of referral to an ophthalmologist depends on specific risk factors (eg, genetic condition, familial eye disease, etc), which can vary

www.pediatrics.org/cgi/doi/10.1542/peds.2008-2624

doi:10.1542/peds.2008-2624

All policy statements from the American Academy of Pediatrics automatically expire 5 years after publication unless reaffirmed, revised, or retired at or before that time.

Key Words

red reflex testing, Bruckner reflex, vision screening

PEDIATRICS (ISSN Numbers: Print, 0031-4005; Online, 1098-4275). Copyright © 2008 by the American Academy of Pediatrics

See RED

Red reflexes from the retinas can be used by the physician to great advantage. The illustration shown here depicts the inequality of the red reflection or the interference with the red reflections in various conditions. The white dots represent corneal light reflexes.

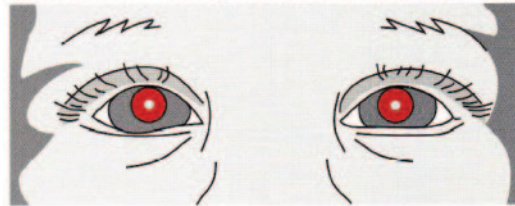
Techniques: Set the ophthalmoscope (preferably one with a halogen light source*) on zero or close to zero, stand a few feet away from the child seated in the parent's lap, attract the child with voice or noise encouraging the child to look at the light, compare the red reflection from each pupil. Both red reflections should be viewed simultaneously and alternately. An expanded observation is the position of the white reflection, the corneal light reflex.

The beauty of this test is that it can be done with a "hands-off" approach; it can furnish accurate information without dilatation of the pupils. As a screening device it is very cost effective. We encourage you to work with this technique. It is useful far beyond all other manual inspection tests for assessments of vision, refraction, motility, alignment, injury evaluations, and eyelid-pupil relationships.

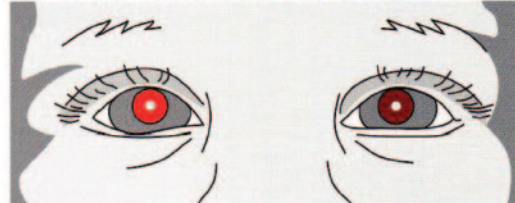


REFERENCE
 Tongue AC, Citis CW: Brückner test. *Ophthalmology*. 1981;88:1041-1044.
 *Welch Allyn Ophthalmoscope # 11720

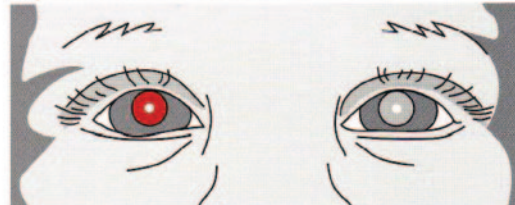
↓ **NORMAL**—Child looks at light. Both red reflections are equal.



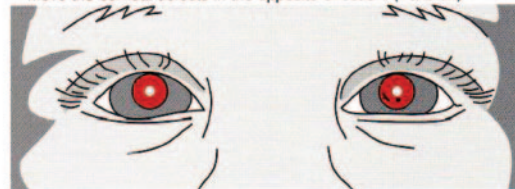↓ **UNEQUAL REFRACTION**—One red reflection is brighter than the other.



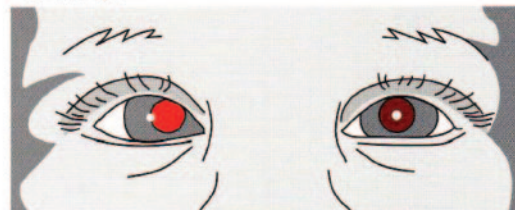↓ **NO REFLEX (CATARACT)**—The presence of lens or other media opacities blocks the red reflection or diminishes it.



↓ **FOREIGN BODY/ABRASION (LEFT CORNEA)**—The red reflection from the pupil will back-light corneal defects or foreign bodies. Movement of the examiner's head in one direction will appear to move the corneal defects in the opposite direction. (Parallax)



↓ **STRABISMUS**—The red reflection is more intense from the deviated eye.



Copyright © 1991, Alfred G. Smith, MD, Miami, FL

FIGURE 1
 Red reflex examination. (Used with permission of Alfred G. Smith, MD, ©1991.)

in age of presentation. However, it is still valuable for the pediatrician to perform red reflex testing on these patients to help determine if it is necessary to expedite this referral. Whenever an opacity or tumor is suspected, an expedited referral is indicated. Because of the urgent nature of diagnosis, it is prudent for the pediatrician to contact the ophthalmologist personally about the possible diagnosis and express (and document) the urgency of the appointment to the parent. It is also essential that the ophthalmologist follow-up with patients, send timely reports to primary care

physicians, and make sure that the transfer of care back to the referring physician is clean and understood by all parties.

The purpose of this policy statement, which is a revision of the previous statement published in 2002,² is to suggest a policy based on current knowledge and experience for examination of the eyes of neonates, infants, and children to minimize the risk of delay in diagnosis of serious vision-threatening or life-threatening disorders.

Occasionally, some pediatricians find that red reflex

testing can be facilitated by dilating the eyes of the subject. Although in infants, pupils are easily dilated by using various agents, significant complications sporadically have been reported with all commercially available dilating eye drops, including sympathomimetic agents such as phenylephrine and anticholinergic agents such as cyclopentolate hydrochloride and tropicamide. These complications include elevated blood pressure and heart rate,³ urticaria,⁴ cardiac arrhythmias,⁵ and contact dermatitis.^{6,7} However, pupillary dilation has been performed routinely for many years in almost all new patients seen by pediatric ophthalmologists, with a very low incidence of toxicity. Hence, this procedure seems to be safe when performed in an office setting on infants older than 2 weeks. Nevertheless, to minimize liability exposure, physicians should discuss with the parents the nature and purpose of the proposed diagnostic procedure and any potential risks associated with the procedure or accompanying medications, including but not limited to pain, discomfort, bradycardia, respiratory depression, and hypertension, and document the provision of this information in the medical chart. Such informed-consent precautions are particularly important when testing preterm infants. Preterm infants seem to be particularly sensitive to the adverse effects of mydriatic eye drops; consequently, the concentration of these pharmacologic agents should be reduced.⁸

SUGGESTED EYE DROPS FOR DILATION IN INFANTS

For infants younger than 9 months:

- A combination drop of 0.25% cyclopentolate with 2.5% phenylephrine (Cyclomydril [Alcon Laboratories, Fort Worth, TX]) approximately 15 minutes before examination.
- Note that atropine drops should be avoided in young infants because of the potential for anticholinergic adverse effects.
- For infants older than 9 months:
- Tropicamide 1%, phenylephrine 2.5% ophthalmic drops; give 1 drop of either or both approximately 15 minutes before red reflex testing.
- A combination drop of 0.2% cyclopentolate with 1% phenylephrine (Cyclomydril) approximately 15 minutes before examination.

RECOMMENDATIONS

- All neonates, infants, and children should have an examination of the red reflex of the eyes performed by a pediatrician or other primary care clinician trained in this examination technique before discharge from the neonatal nursery and during all subsequent routine health supervision visits.
- The result of the red reflex examination is to be rated as normal when the reflections of the 2 eyes viewed both individually and simultaneously are equivalent in color, intensity, and clarity and there are no opac-

ities or white spots (leukokoria) within the area of either or both red reflexes.

- All infants or children with an abnormal Bruckner reflex or absent red reflex should be referred immediately to an ophthalmologist who is skilled in pediatric examinations.
- It is essential that the referring practitioner communicate the abnormal findings directly to the ophthalmologist and receive confirmation back from the ophthalmologist that proper follow-up consultation was performed.
- Infants or children in high-risk categories, including relatives of patients with retinoblastoma, infantile or juvenile cataracts, retinal dysplasia, glaucoma, or other vision-threatening ocular disorders that can present in infancy, should not only have red reflex testing performed in the nursery but also be referred to an ophthalmologist who is experienced in examining children for a complete eye examination regardless of the findings of the red reflex testing by the pediatrician.
- Infants or children in whom parents or other observers describe a history suspicious for the presence of leukokoria (a white pupil reflex) in 1 or both eyes should be examined by an ophthalmologist who is experienced in the examination of children, because small retinoblastoma tumors or other serious lesions may present in a subtle fashion.

SECTION ON OPHTHALMOLOGY, 2005–2006

Edward J. Buckley, MD, Chairperson
 George S. Ellis, Jr, MD, Chairperson-Elect
 Stephen Glaser, MD
 David Granet, MD
 Jane D. Kivlin, MD
 Gregg T. Lueder, MD
 *James B. Ruben, MD
 Maynard B. Wheeler, MD

IMMEDIATE PAST CHAIRPERSON

Steven J. Lichtenstein, MD

LIAISONS

Kyle A. Arnoldi, CO
 American Association of Certified Orthoptists
 Christie L. Morse, MD
 American Academy of Ophthalmology
 Michael X. Repka, MD
 American Association for Pediatric Ophthalmology and Strabismus

STAFF

S. Niccole Alexander, MPP

*Lead author

REFERENCES

1. American Academy of Pediatrics, Committee on Practice and Ambulatory Medicine, Section on Ophthalmology; American Association of Certified Orthopedists; American Association for

- Pediatric Ophthalmology and Strabismus; American Academy of Ophthalmology. Eye examination in infants, children, and young adults by pediatricians. *Pediatrics*. 2003;111(4 pt 1):902-907
2. American Academy of Pediatrics, Section on Ophthalmology. Red reflex examination in infants and children. *Pediatrics*. 2002;109(5):980-981
 3. Oğüt MS, Bozkurt N, Ozek E, Birgen H, Kazakoğlu H, Oğüt M. Effects and side effects of mydriatic eyedrops in neonates. *Eur J Ophthalmol*. 1996;6(2):192-196
 4. Fraunfelder FT. Pupil dilation using phenylephrine alone or in combination with tropicamide. *Ophthalmology*. 1999;106(1):4
 5. Gaynes BI. Monitoring drug safety: cardiac events in routine mydriasis. *Optom Vis Sci*. 1998;75(4):245-246
 6. Resano A, Esteve C, Fernandez Benitez M. Allergic contact blepharoconjunctivitis due to phenylephrine eye drops. *J Investig Allergol Clin Immunol*. 1999;9(1):55-57
 7. Boukhman MP, Maibach HI. Allergic contact dermatitis from tropicamide ophthalmic solution. *Contact Dermatitis*. 1999;41(1):47-48
 8. Chew C, Rahman RA, Shafie SM, Mohamad Z. Comparison of mydriatic regimens used in screening for retinopathy of prematurity in preterm infants with dark irides. *J Pediatr Ophthalmol Strabismus*. 2005;42(3):166-173